

# Orthodontic Treatment and Mini Wing Osteotomy: A Case Report of Changes in Facial Aesthetic

FERNANDA RAMOS DE FARIA<sup>1</sup>, SERGIO LUIZ MOTA-JÚNIOR<sup>2</sup>, LEONARDO METROPOLO MOREIRA<sup>3</sup>, ALUAN COSTA UNGIEROWICZ<sup>4</sup>, MARCO ABDO GRAVINA<sup>5</sup>



## ABSTRACT

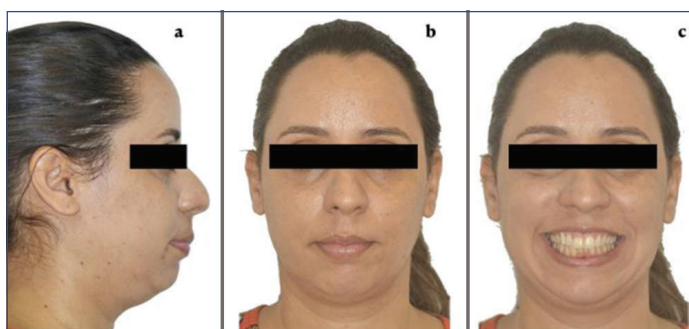
For correction of dentofacial deformities, orthosurgical treatment is recommended and often involves bi-maxillary orthognathic surgery. The chin area is an important key for a harmonious facial profile and plays an important role. The present case (of a 38-year-old female) describes one successful surgical-orthodontic treatment. The treatment consisted of the use of an Edgewise fixed appliance (0.022"×0.028"), mini Wing osteotomy (mWo), correction of the deviated nasal septum, and rhinoplasty. The treatment resulted in a better facial harmony and aesthetic with greater definition and lengthening of the submental region, adipose tissue elimination, and an upturned nose due to the correction of the deviated nasal septum associated with rhinoplasty. The Class I canine and molar relationship, the upper and lower midlines coincident with the facial midline, and the compensatory projection of the lower incisors were maintained. A satisfactory overbite and overjet, and leveled curve of Spee were obtained. In conclusion, the orthodontic treatment associated with mWo, correction of the deviated nasal septum, and rhinoplasty surgery provided satisfactory functional and aesthetic results.

**Keywords:** Cephalometry, Chin wing, Orthognathic surgery, Orthosurgical treatment, Rhinoplasty

## CASE REPORT

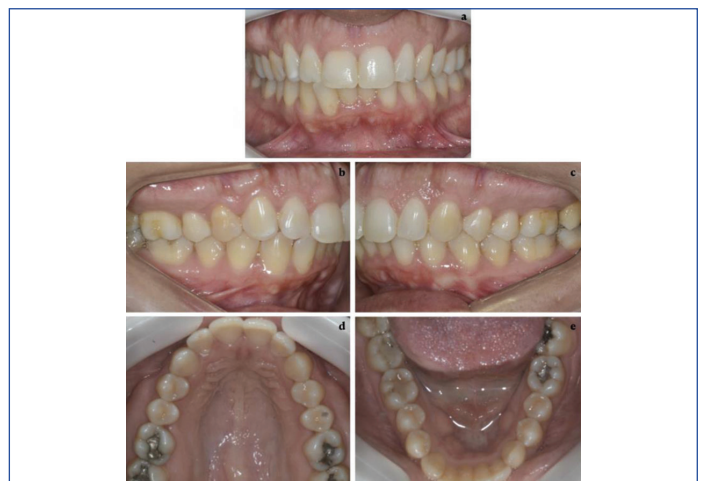A 38-year-old female patient sought orthodontic treatment due to dissatisfaction with anteroinferior crowding and the lingual position and rotation of tooth 22. The patient also reported difficulty in breathing, especially during physical activity, such as running.

The extraoral examination showed a convex profile with anteroposterior mandibular deficiency, a short and undefined submental region with adipose tissue, and a deviated nasal septum to the left-side [Table/Fig-1a-c]. In addition, a Class I canine and molar relationship, an overbite of 3.0 mm, an overjet of 1.5 mm, a deep lower curve of Spee, upper and lower midlines coincident with the facial midline, lingual position of tooth 22, rotation of teeth 22 and 24, a buccal and distal inclination of tooth 42, and anteroinferior crowding were observed [Table/Fig-2a-e].

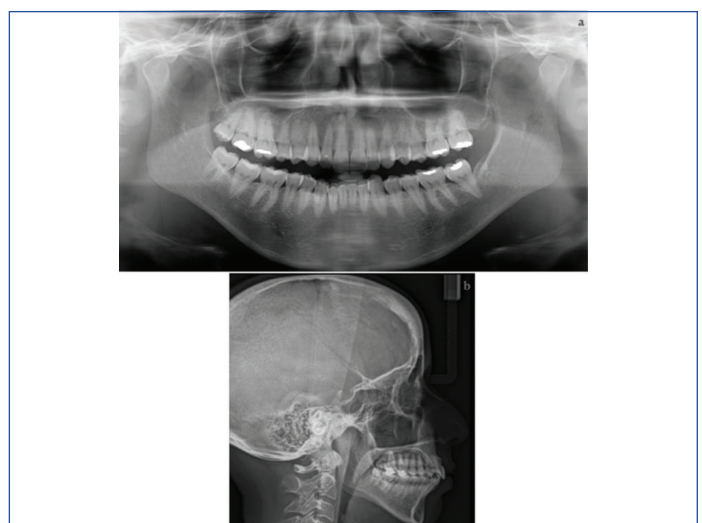


[Table/Fig-1]: Pretreatment extraoral photographs: a) Lateral; b) Frontal; c) Smile.

Radiographs showed permanent dentition with the absence of teeth 28 and 38, satisfactory root parallelism in both dental arches, and a deviated nasal septum to the left-side [Table/Fig-3]. Cephalometry showed a skeletal Class II malocclusion (ANB, 8.9°), maxillary protrusion (SNA, 86.4°), mandibular retrusion (SNB, 77.5°), dolichofacial growth pattern (SN.GoGn, 38.6°; FMA: 31.0°), compensatory retroinclination of the upper incisors (UI.NA, 16.9°; UI-NA, 2.8 mm), compensatory projection of the lower incisors (LI.NB, 38.9°; LI-NB, 12.2 mm), and a reduced interincisal angle (I.I, 115.2°), due to the proclination of the lower incisors [Table/Fig-3a,b,4].



[Table/Fig-2]: Pretreatment intraoral photographs: a) Frontal; b) Right-side; c) Left-side; d) Upper occlusal; e) Lower occlusal.



[Table/Fig-3]: a) Initial panoramic radiograph; b) Initial lateral cephalometric radiograph.

Cephalometric measurements	Measurement	Norm	Pre-treatment	Post-treatment
Skeletal pattern	SNA (°)	82	86.4	86.4
	SNB (°)	80	77.5	77.5
	ANB (°)	2	8.9	8.9
	AO-BO (mm)	0	5.5	5.5
	Y-Axis (°)	59.4	58.2	57.9
	Go-Gn.SN (°)	32	38.6	36.8
	FMA (°)	25	31.0	28.5
Dental pattern	IMPA (°)	90	102.5	101.5
	UI.NA (°)	22	16.9	15
	UI-NA (mm)	4	2.8	2.5
	LI.NB (°)	25	38.9	38.5
	LI-NB (mm)	4	12.2	12
	1.1 (°)	131	115.2	118
Profile	S-UL (mm)	0	2	0
	S-LL (mm)	0	3	-1
	Z-Angle (°)	75	65.5	80

**[Table/Fig-4]:** Cephalometric measurements.

ANB: Angle between point-A, Nasion (N) and point-B; AO-BO: A and B contact points on Occlusal plane; FMA: Frankfort-Mandibular plane Angle; Go-Gn.SN: Gonial-Gnathion Sella-Nasion; IMPA: Incisor Mandibular Plane Angle; SNA: Sella-Nasion-point-A; SNB: Sella-Nasion-point-B; S-LL: Spacer-Lower Left (quadrant); S-UL: Spacer-Upper Left (quadrant); UI.NA (o): Angle (in degrees) between Upper Incisor and Nasion point-A; UI.NA (mm): Distance (in millimeters) between Upper Incisor and Nasion point-A; LI.NB (o): Angle (in degrees) between Lower Incisor and Nasion point-B; LI.NB (mm): Distance (in millimeters) between Lower Incisor and Nasion point-B; Z-angle: Angle formed by intersection of Frankfort horizontal plane and a line connecting the soft tissue pogonion and the most protrusive lip

**Treatment objectives:** To obtain functional occlusion and harmonious and aesthetic face.

**Treatment alternatives:**

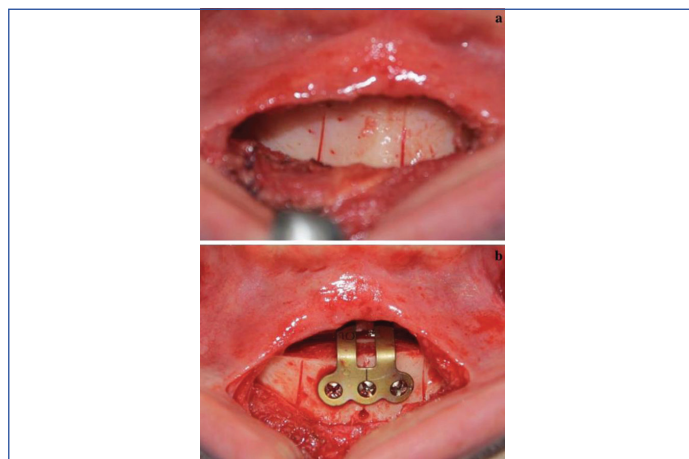
- 1) Orthodontic treatment+correction of the deviated nasal septum+rhinoplasty. This alternative would satisfy the patient's main complaint but would not improve the facial aesthetic.
- 2) Orthodontic treatment+orthognathic surgery with mandibular advancement+correction of the deviated nasal septum+rhinoplasty. This alternative would require a pre-surgical procedure to increase the overjet by decompensating the upper and lower incisors.
- 3) Orthodontic treatment+mWo+correction of the deviated nasal septum+rhinoplasty. This alternative would be the most conservative for achieving satisfactory functional and aesthetic results, without the need of premolars extraction.

**Treatment process:** Monocrystalline sapphire ceramic brackets (Eurodonto, Zetta, Roth 0.022"x0.028", Curitiba, Paraná, Brazil) were bonded on teeth 15 to 25. Metal brackets (Abzil, Edgewise Standard 0.022"x0.028", Sumaré, São Paulo, Brazil) were bonded on teeth 35 to 45. Open brackets and metal tubes (Morelli, Edgewise Standard 10.30.210 and 20.31.201, Sorocaba, São Paulo, Brazil) were bonded on the upper and lower first molars and second molars, respectively. The alignment and leveling phases were carried out with 0.012" and 0.014" nickel-titanium archwires and 0.016", 0.018", and 0.020" upper and lower coordinated stainless steel archwires.

The anteroinferior crowding was corrected with a 0.20 mm Interproximal Reduction (IPR) from the mesial of tooth 33 to the mesial of tooth 43. The anterosuperior crowding was corrected with a 0.10 mm IPR from the mesial of tooth 13 to the mesial of tooth 23. The lower curve of Spee was leveled with a 0.018" and 0.020" stainless steel archwire through the intrusion of the anteroinferior segment. This intrusion was carried out using step-down bends from 33 to 43. Boot-loop bends were inserted in the distal teeth 33 and 43 to achieve resilience, increase flexibility, and fit get better to the brackets. Step-up bends were used to intrude the upper

central incisors using 0.018" and 0.020" stainless steel archwire. This reduced the exposure of the incisors at rest and gingival.

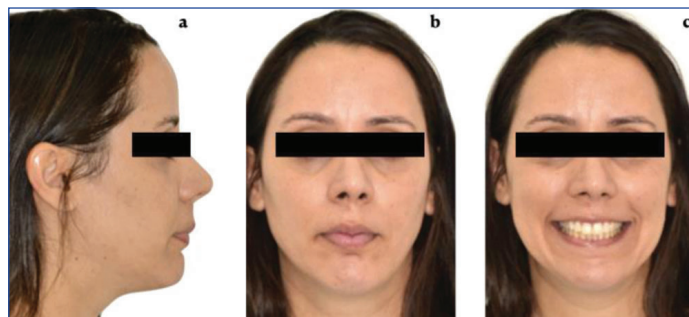
The patient was referred for the mWo and rhinoplasty six months before completing the orthodontic treatment. The patient's dental arches were scanned, and the DICOM files were reconstructed using Dolphin (Dolphin Imaging and Management Solutions, CA, USA). After the surgical planning, the three-dimensional model was converted into Standard Tessellation Language (STL) to be used for designing the osteotomies and surgical guides. The surgical procedures were performed under general anaesthesia. One buccal incision in the symphysis area was made by using an electric scalpel [Table/Fig-5a,b]. Reciprocating micro-saws (Stryker-CORE System, Michigan, USA) were used to cut the bone areas. After the osteotomies, one plate (System 2.0, KLS Martin, Germany) in the symphysis area was placed for the rigid internal fixation [Table/Fig-5].



**[Table/Fig-5]:** a) Buccal incision; b) Mini Wing osteotomy with plate in the symphysis area.

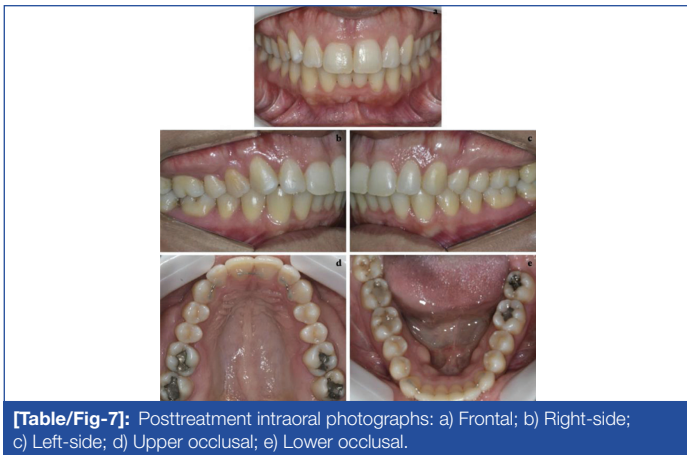After removing the fixed appliance, fixed retainers made of 0.020" stainless steel wire were bonded between teeth 11-21, 12-13, and 22-23 in the upper arch. In the lower arch, a fixed retainer made of 0.020" stainless steel wire was bonded from teeth 33 to 43. The patient was also provided with an upper removable wraparound retainer to wear only during nighttime.

**Treatment results:** The patient obtained a better facial harmony and aesthetic with greater definition and lengthening of the submental region, adipose tissue elimination, and an upturned nose due to the correction of the deviated nasal septum associated with rhinoplasty [Table/Fig-6a-c]. The patient also reported a significant improvement in her breathing, especially during running.



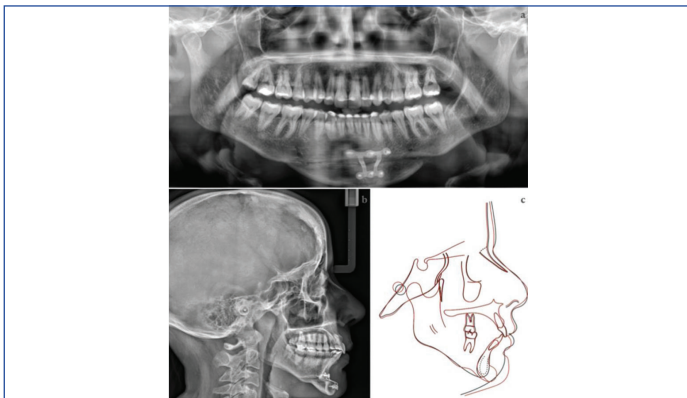
**[Table/Fig-6]:** Posttreatment extraoral photographs: a) Lateral; b) Frontal; c) Smile.

The Class I canine and molar relationship was maintained. An overbite of 2.0 mm and an overjet of 1.0 mm were obtained due to the intrusion of the upper central incisors. This intrusion improved the gingival smile and the exposure of the upper incisors [Table/Fig-6c]. In addition, the upper and lower midlines coincident with the facial midline and the compensatory projection of the lower incisors were maintained [Table/Fig-4], while the lower curve of Spee was leveled, improving the overbite [Table/Fig-7a-c].



**[Table/Fig-7]:** Posttreatment intraoral photographs: a) Frontal; b) Right-side; c) Left-side; d) Upper occlusal; e) Lower occlusal.

Radiographs showed satisfactory root parallelism and the presence of the fixation plate used in the mWo [Table/Fig-8a-b].



**[Table/Fig-8]:** a) Final panoramic radiograph; b) Final lateral cephalometric radiograph; c) Superimposition cephalometric tracing.

## DISCUSSION

The desired facial aesthetic may not be achieved when there is dental compensation for skeletal Class II malocclusion. In this situation, surgical techniques should be considered [1].

Chin Wing osteotomy (CWo) is a surgical technique that can change the morphology of the mandibular base in patients with anteroposterior mandibular deficiency associated with satisfactory occlusion [1,2]. This technique can modify the osteotomy according to each case. mWo is one modification of this technique [3].

In CWo, the osteotomy is performed underneath the inferior alveolar nerve, repositioning the entire bone base [2,4-7]. In the mWo, only part of the mandibular base is repositioned [3]. Both techniques should only be indicated if the patient already presents dental compensation for the skeletal discrepancy [1]. In this study, the case showed dental compensation and only required an orthodontic refinement. Thus, the mWo technique was selected since it is less invasive than CWo and results in a good facial aesthetic [3]. Although mWo is little reported and discussed in the literature, there is one similar case described [3].

The compensatory projection of the lower incisors was naturally obtained, allowing greater stability to their positions [8]. However, some occlusal refinements were performed during the orthodontic treatment, such as reducing the gingival smile and the exposure of the upper incisors. Rhinoplasty was also performed with the mWo during the orthodontic treatment, giving the patient greater facial harmony, function and aesthetics.

## CONCLUSION(S)

The orthodontic treatment associated with mWo and rhinoplasty surgeries provided satisfactory functional and aesthetic results. The treatment was successful in occlusal results and facial aesthetics. mWo should be considered as a form of treatment for patients who present this type of skeletal condition.

## REFERENCES

- [1] Barros HLM, Demétrio MS, Barbosa SM, Rêgo MVNN, Marlière DAA. Chin Wing osteotomy for improving mandible projection and contour in patients with normal occlusion: Case reports. *Maxillofac Oral Surg.* 2022;21(2):521-29.
- [2] Pouzoulet P, Cheynet F, Guyot L, Foletti JM, Chossegros C, Cresseaux P. Chin wing: Technical note. *J Stomatol Oral Maxillofac Surg.* 2018;119(4):315-18.
- [3] Cordier G, Sigaux N, Carlier A, Ibrahim B, Cresseaux P. Mini wing osteotomy: A variant of chin wing osteotomy. *J Stomatol Oral Maxillofac Surg.* 2020;121(3):282-85.
- [4] Triaca A, Minorette R, Saulacic N. Mandibular wing osteotomy for correction of the mandibular plane: A case report. *Br J Oral Maxillofac Surg.* 2010;48(3):182-84.
- [5] Lopez PE, Guerrero CA, Mujica EU. Mandibular basal osteotomy: New designs and fixation techniques. *J Oral Maxillofac Surg.* 2011;69:786-97.
- [6] Tabrizi R, Pourdanesh F, Soleimanpour M, Shafie E. Evaluation of mandibular wing osteotomy in obstructive sleep apnea cases with retrognathia. *J Maxillofac Oral Surg.* 2015;14(1):46-50.
- [7] Lutz JC, Schouman T, Meyer C, Savoldelli C, Louvrier A. Chin wing osteotomy using customised guide and implants: An improvement for a safer and swifter procedure: Technical note. *Br J Oral Maxillofac Surg.* 2021;59(1):129-31.
- [8] Kantarci A, Will L, Yen S. Tooth movement. *Front Oral Biol.* 2016;18:56-63.

### PARTICULARS OF CONTRIBUTORS:

1. PhD Student, Department of Orthodontics, Federal University of Juiz de Fora, Juiz de Fora, Minas Gerais, Brazil.
2. Private Practitioner and Professor of Department of Orthodontics, Federal University of Juiz de Fora, Juiz de Fora, Minas Gerais, Brazil.
3. Private Practitioner, Private Practice of the Orthognathic Surgery, Rio de Janeiro, Brazil.
4. Private Practitioner, Private Practice of the Otolaryngology, Rio de Janeiro, Brazil.
5. Professor of Department of Orthodontics, Federal University of Juiz de Fora, Juiz de Fora, Minas Gerais, Brazil.

### NAME, ADDRESS, E-MAIL ID OF THE CORRESPONDING AUTHOR:

Fernanda Ramos de Faria,  
Honório Antônio da Silva, 620/202, São Pedro,  
Juiz de Fora/MG, Brazil Zip: 36037-310.  
E-mail: fernandaramosfaria@gmail.com

### AUTHOR DECLARATION:

- Financial or Other Competing Interests: None
- Was informed consent obtained from the subjects involved in the study? Yes
- For any images presented appropriate consent has been obtained from the subjects. Yes

### PLAGIARISM CHECKING METHODS: [Jain H et al.]

- Plagiarism X-checker: Oct 17, 2023
- Manual Googling: Nov 14, 2023
- iThenticate Software: Jan 13, 2024 (14%)

### ETYMOLOGY: Author Origin

EMENDATIONS: 7

Date of Submission: **Oct 16, 2023**  
Date of Peer Review: **Nov 16, 2023**  
Date of Acceptance: **Jan 15, 2024**  
Date of Publishing: **Mar 01, 2024**